

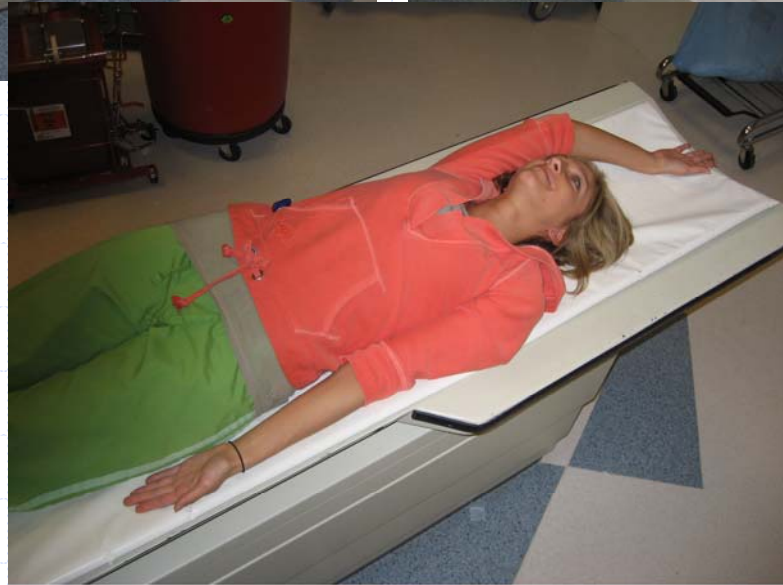
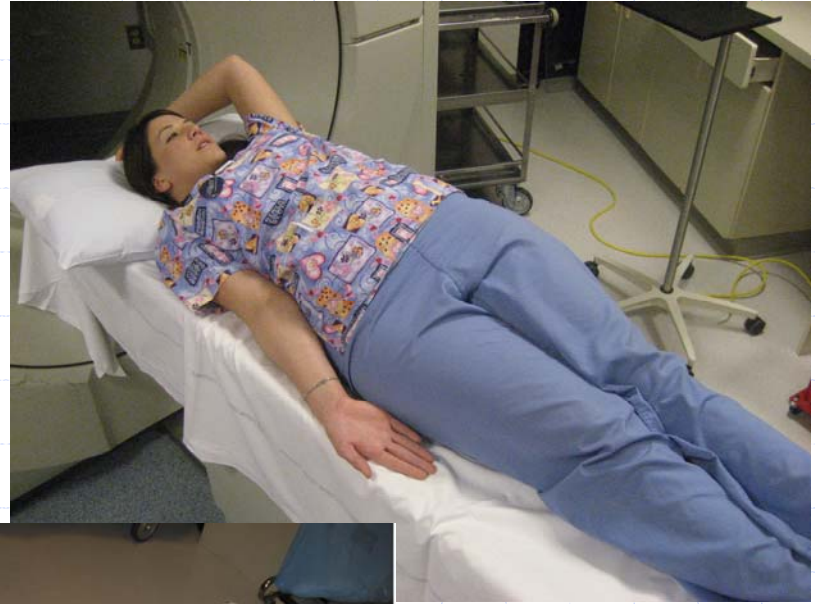
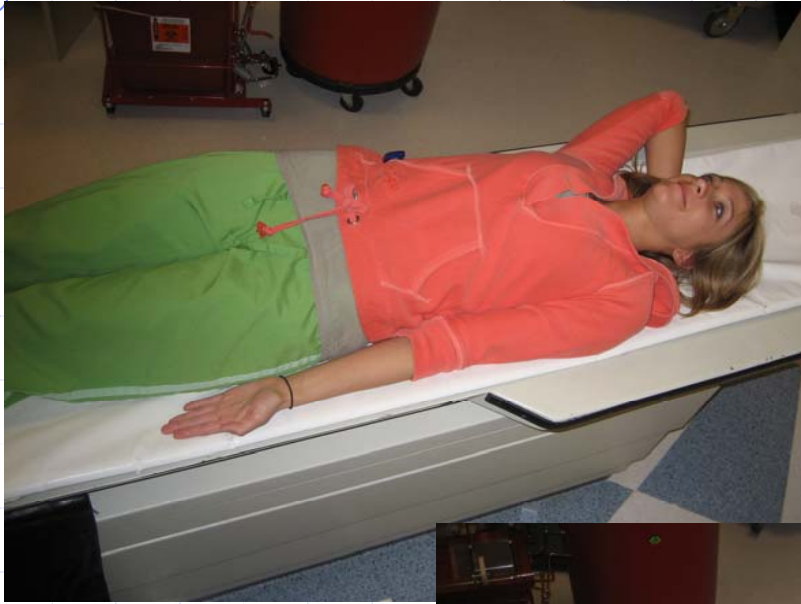UPPER EXTREMITY

SHOULDER

◆ Positioning

- Patient supine
- Affected arm by side of body
- Contralateral arm raised above head.

SHOULDER

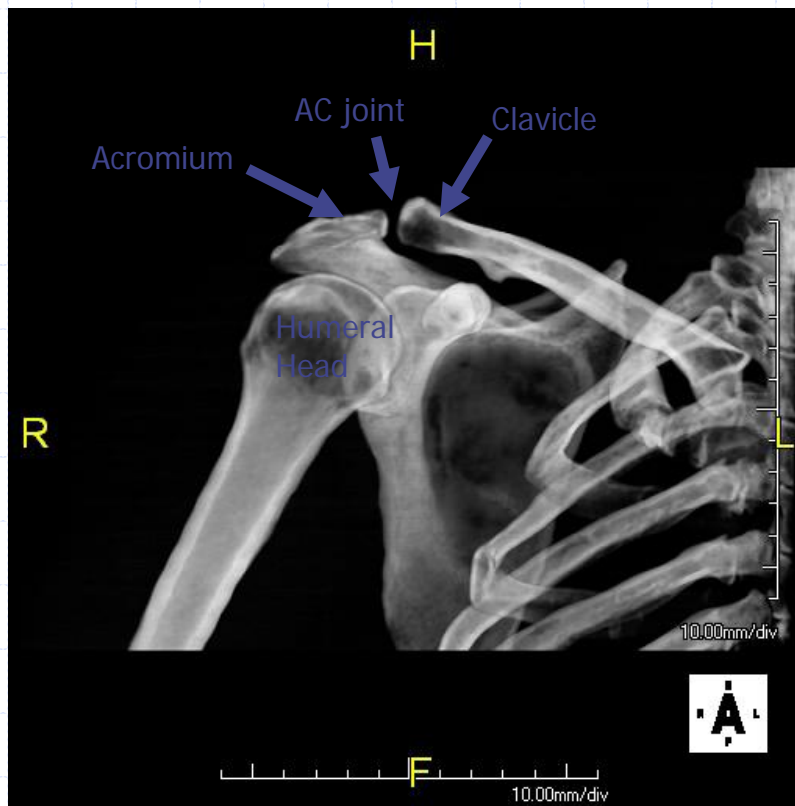


SHOULDER

Gantry Tilt	FOV	KV	mA
0	Large	140	200
	Slice (mm)	Interval (mm)	Type/Plane
Reconstruct	1.25	0.62	-Bone -Soft Tissue
Reformat	2	2	-Axial -Coronal -Sagittal

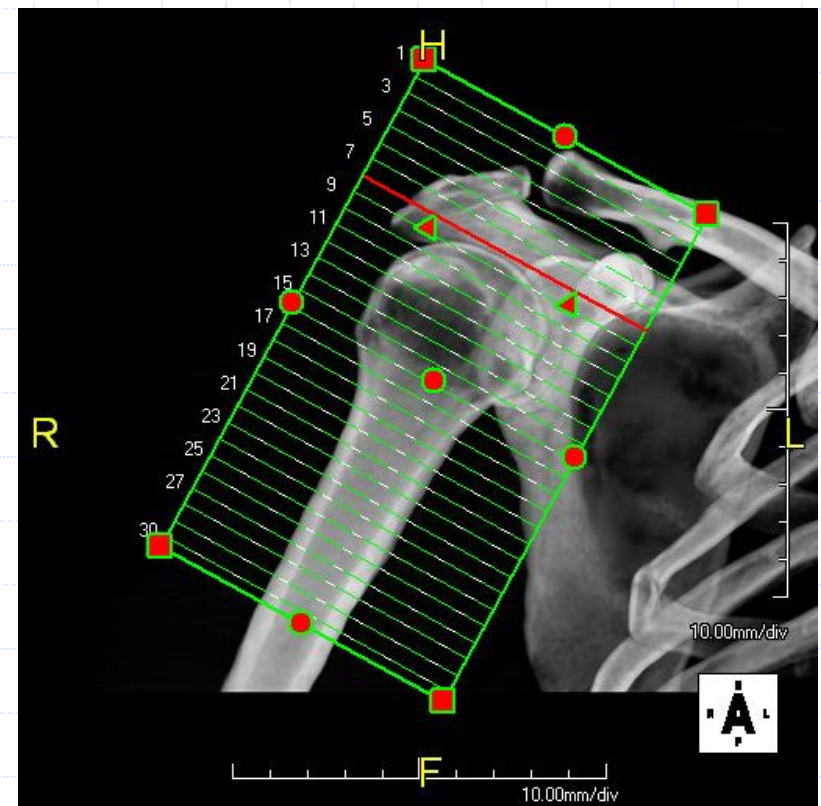
SHOULDER

Relevant Anatomy



Scanning Plane

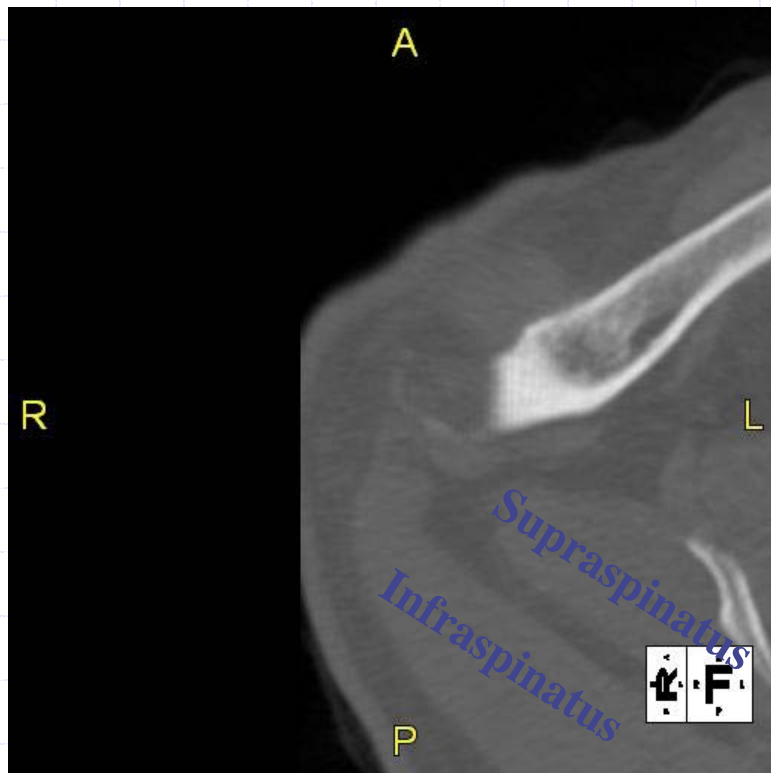
- Prescribe plane parallel to humeral shaft.
- Cover from AC joint through proximal humeral diaphysis.



SHOULDER

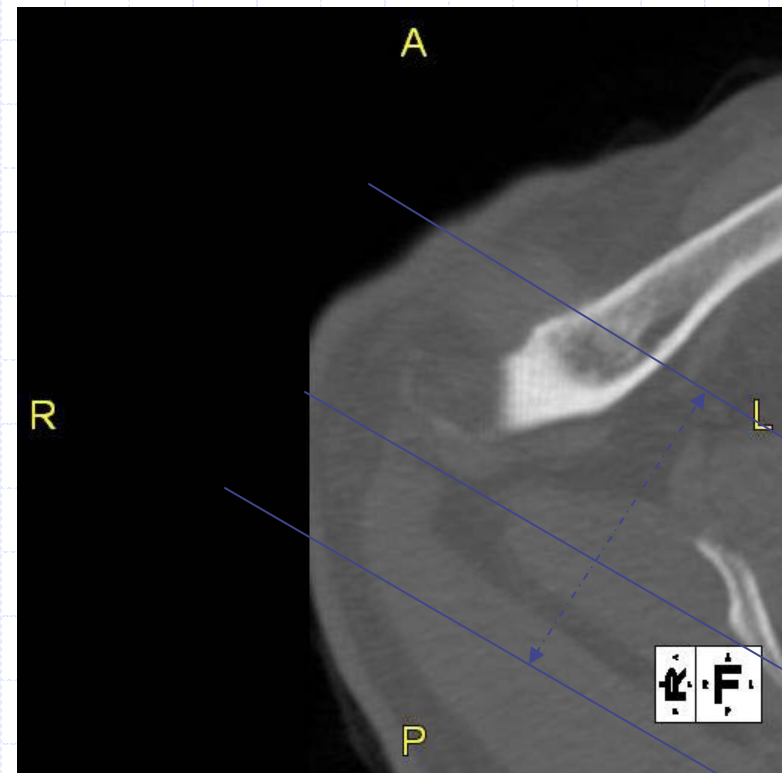
Coronal Imaging Plane

Relevant Anatomy



Coronal Imaging Plane

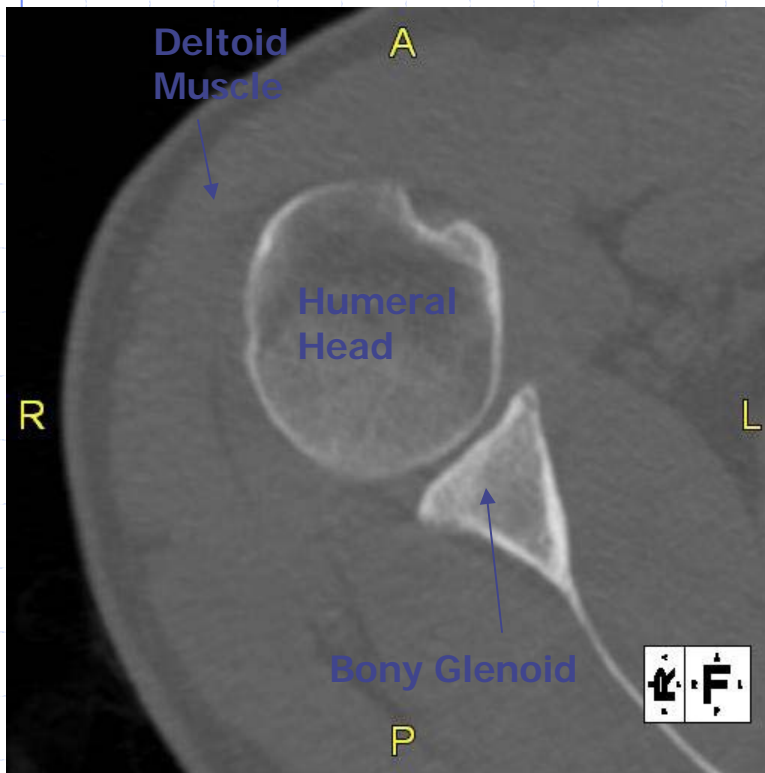
- Prescribe coronal plane off of axial images parallel to supraspinatus muscle



SHOULDER

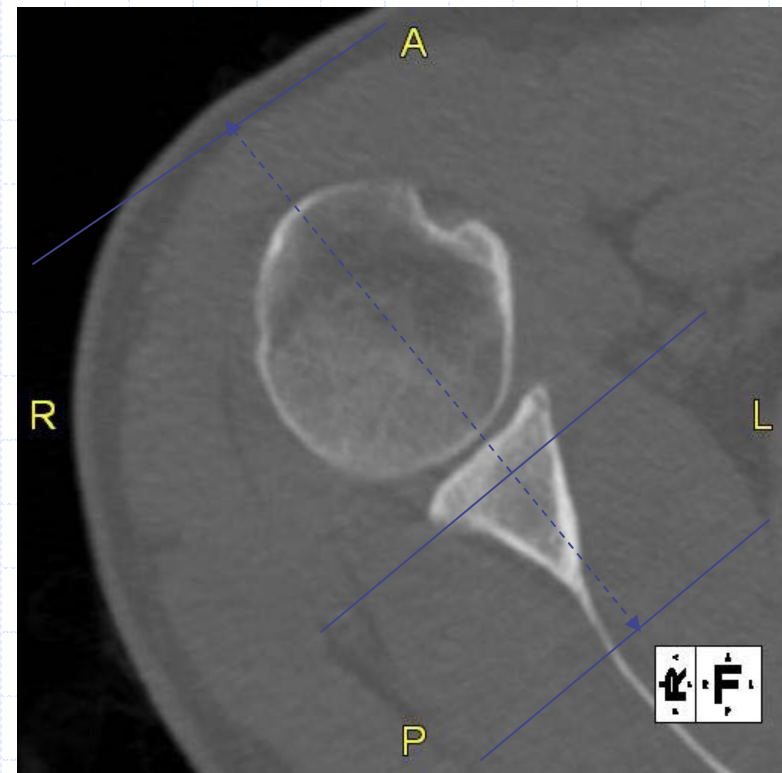
Sagittal Imaging Plane

Relevant Anatomy



Sagittal Imaging Plane

- Prescribe sagittal plane off axial images with line parallel to bony glenoid.
- Image from scapular wing through deltoid muscle.

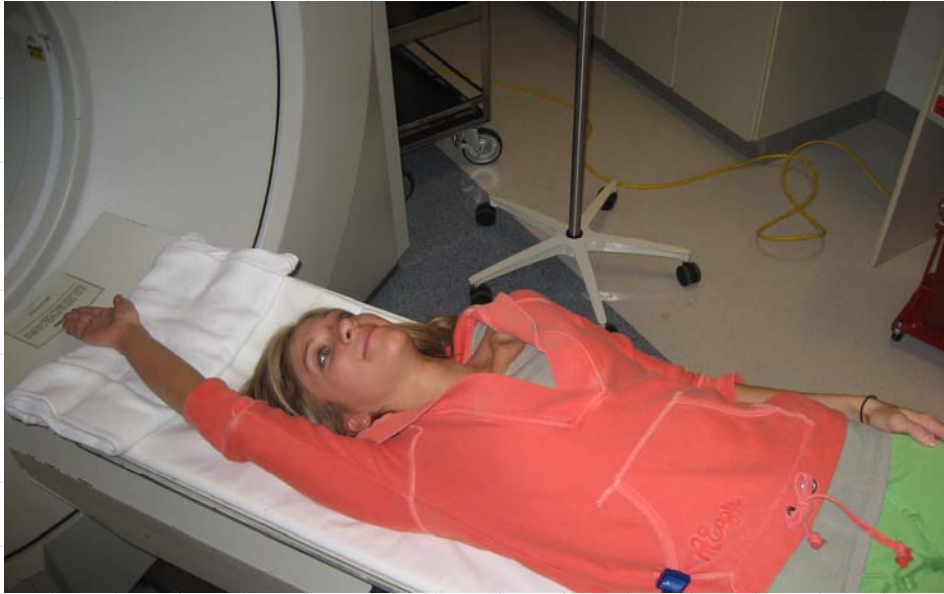

ELBOW

◆ Positioning

- Patient supine
- Arm by side or raised above head
- Palm up

ELBOW



ELBOW

Gantry Tilt	FOV	KV	mA
0	Small	120	150
	Slice (mm)	Interval (mm)	Type/Plane
Reconstruct	0.625	0.3	-Bone -Soft Tissue
Reformat	0.8	1.5	-Axial -Coronal -Sagittal

Elbow

Relevant Anatomy

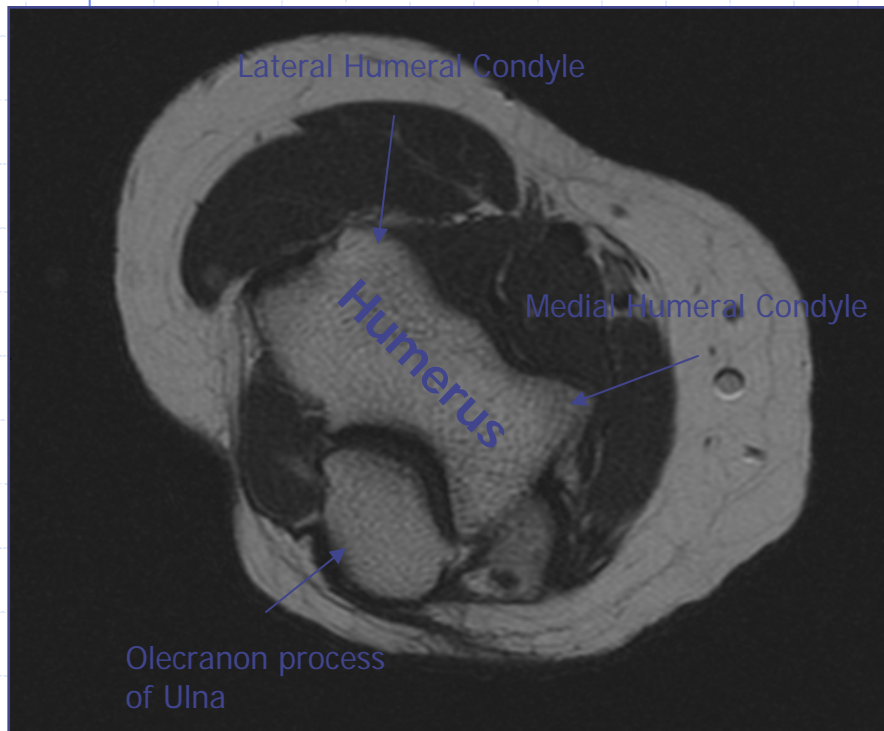
Scanning Plane

- Prescribe plane perpendicular to coronal plane (©).
- Scan from humeral diaphysis past radial tuberosity

ELBOW

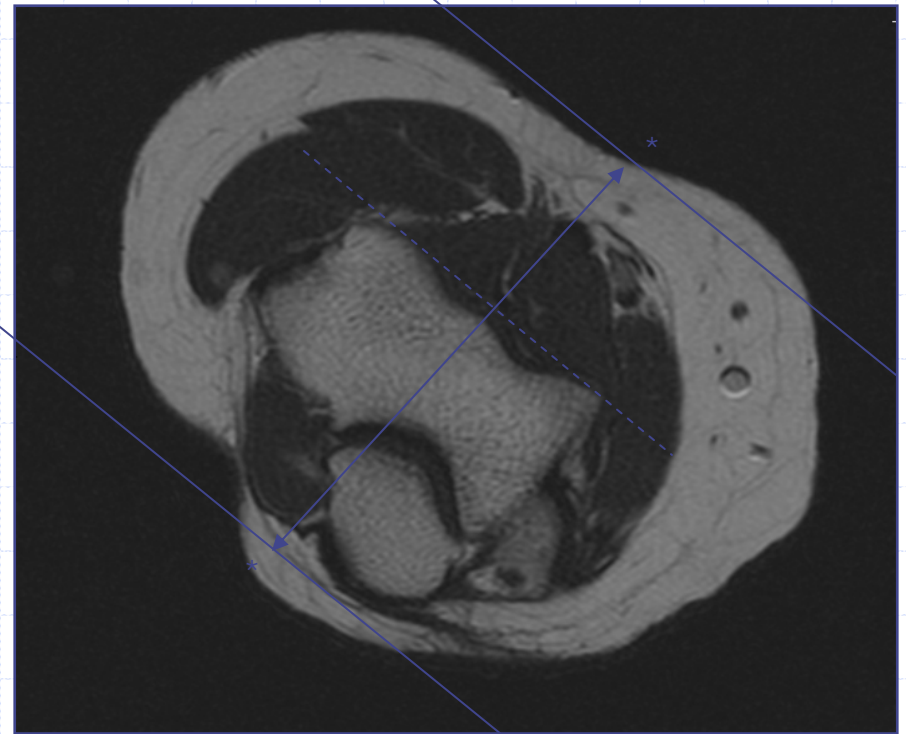
Coronal Imaging Plane

Relevant Anatomy



Coronal Imaging Plane

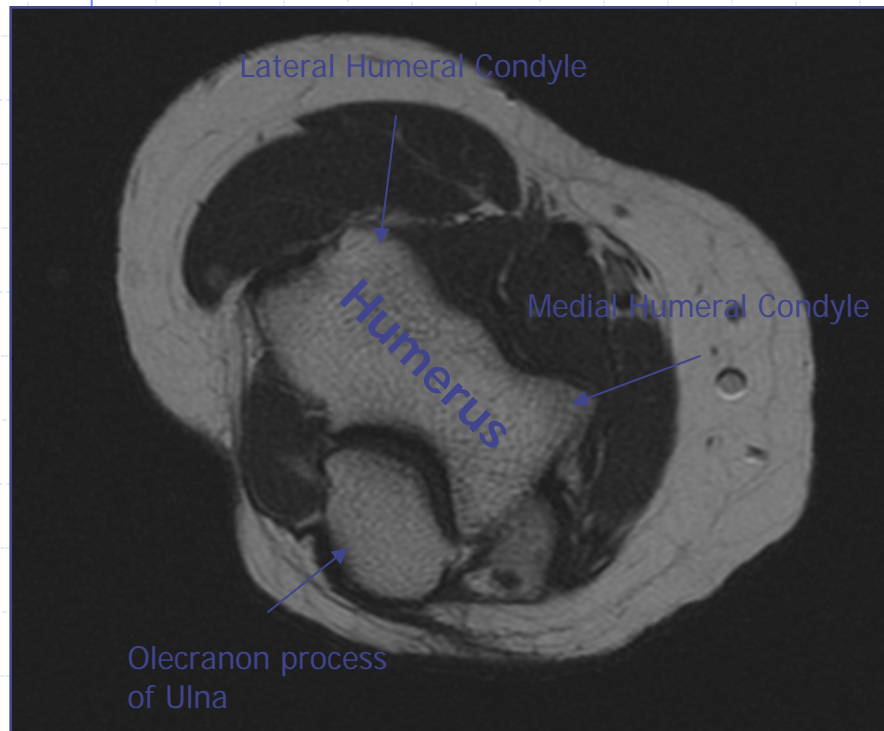
*Prescribe plane parallel to anterior humerus at condyles. Scan through entire elbow.



ELBOW

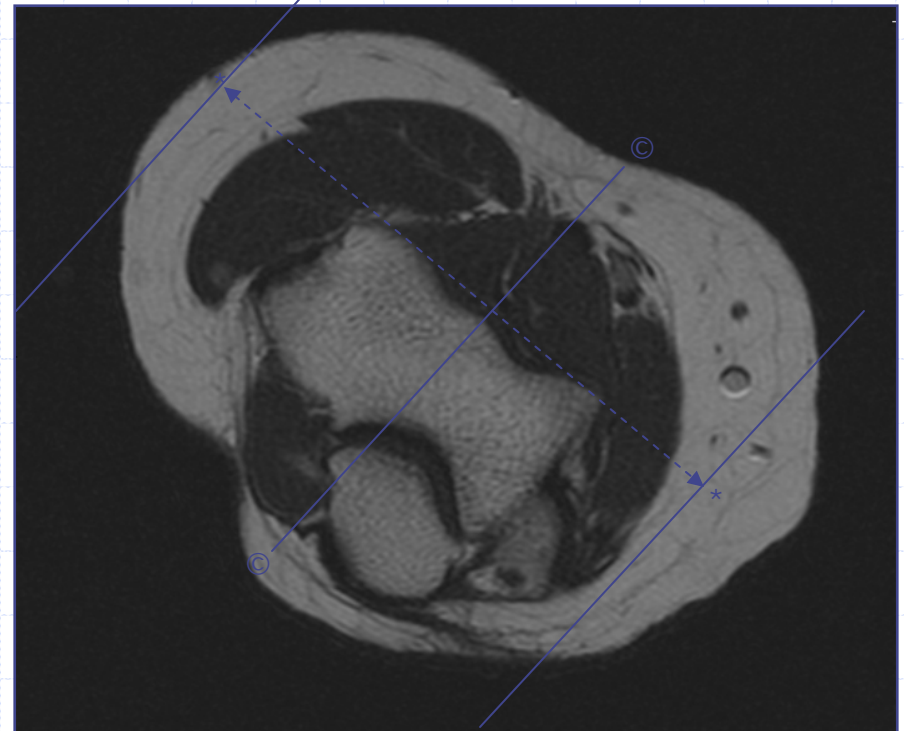
Sagittal Imaging Plane

Relevant Anatomy



Sagittal Imaging Plane

*Prescribe plane perpendicular to coronal plane (©). Scan through entire elbow.

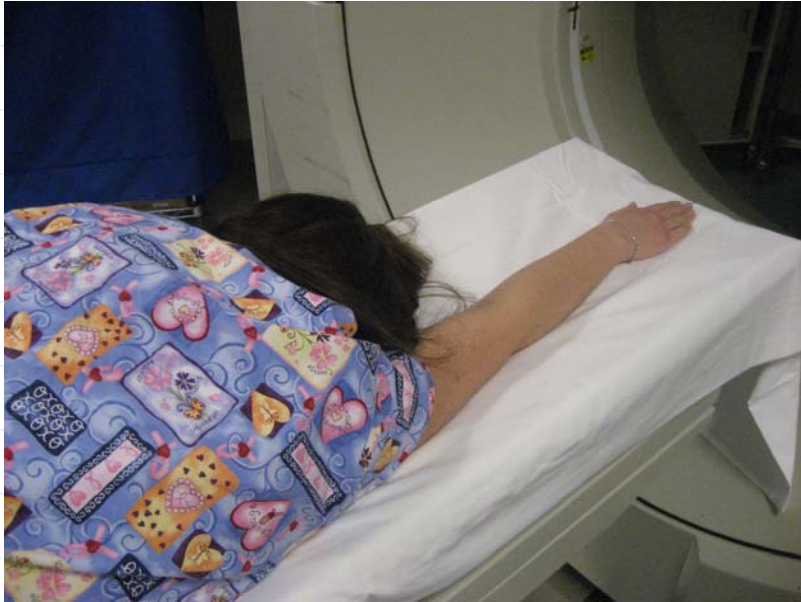
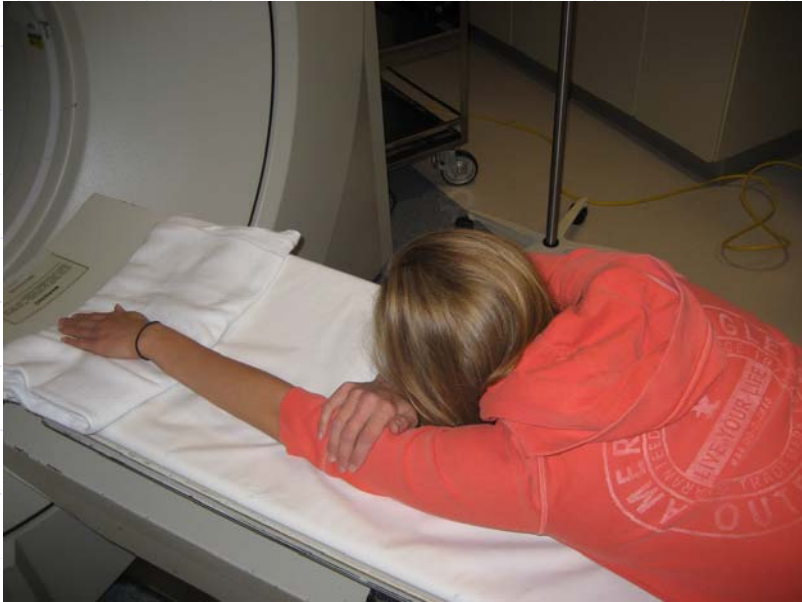
WRIST

◆ Positioning

- Patient prone
- Arm over head ("Mighty Mouse Position")
- Arm as straight as possible
- Wrist centered in gantry

WRIST

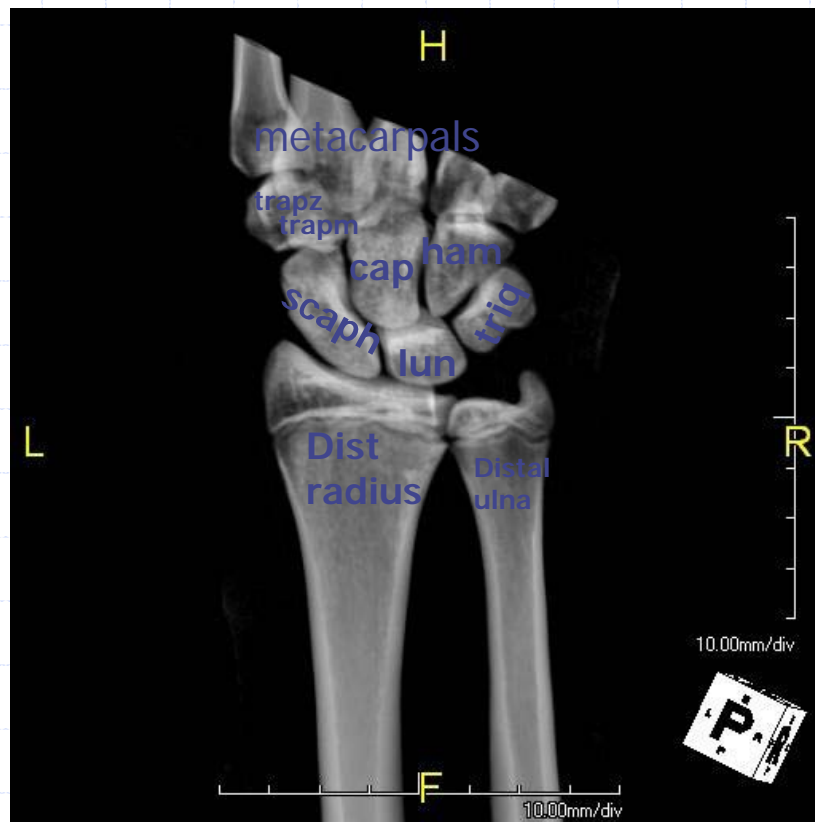


WRIST

Gantry Tilt	FOV	KV	mA
0	Small	120	150
	Slice (mm)	Interval (mm)	Type/Plane
Reconstruct	0.625	0.3	-Bone -Soft Tissue
Reformat	0.8	1.5	-Axial -Coronal -Sagittal

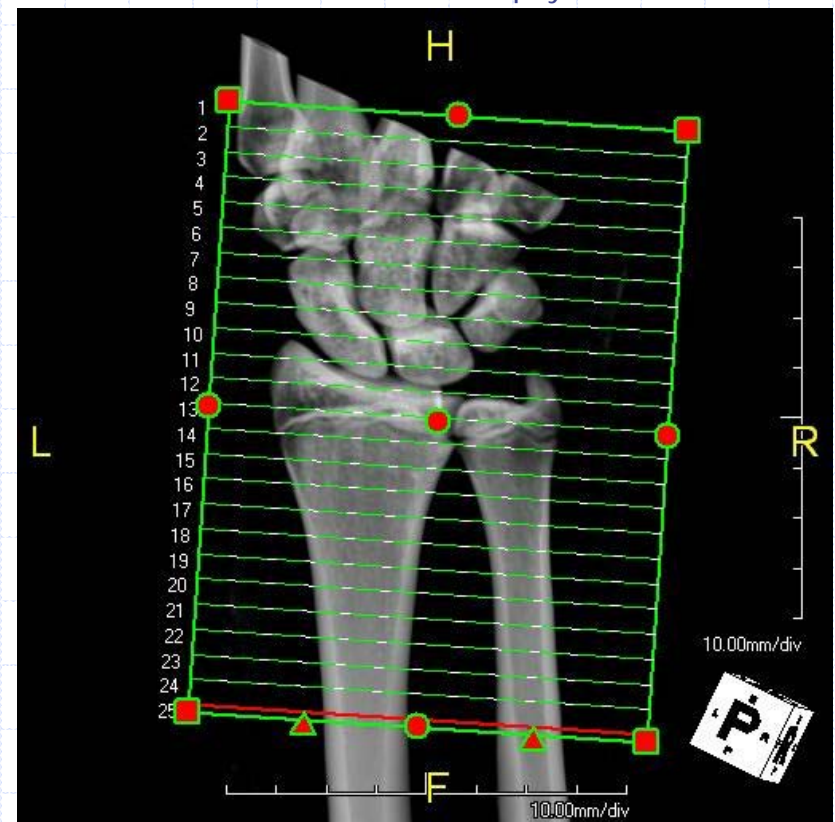
WRIST

Relevant Anatomy



Scanning Plane

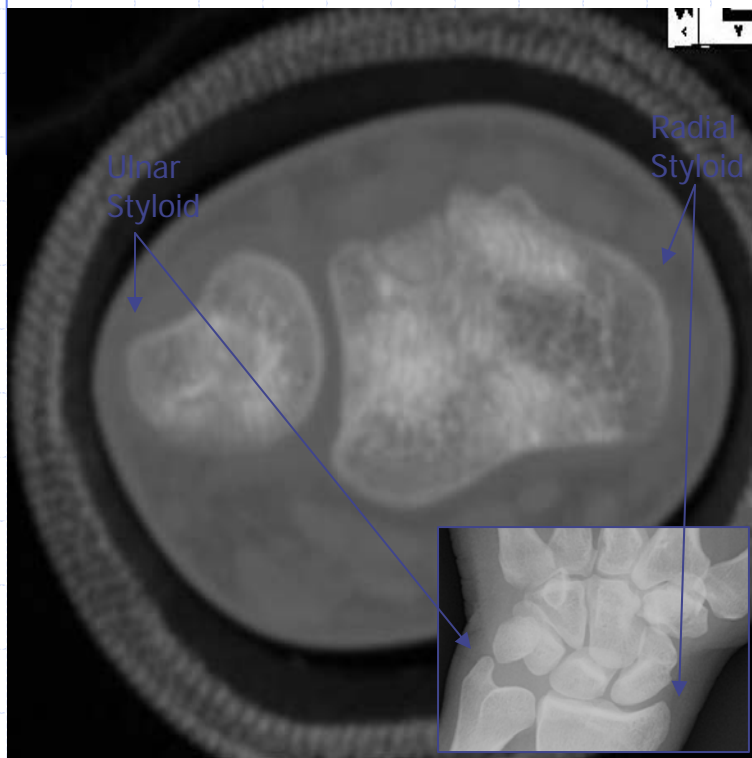
- Prescribe plane parallel to distal radius.
- Scan from proximal metacarpals through distal radial/ulnar metaphysis.



WRIST

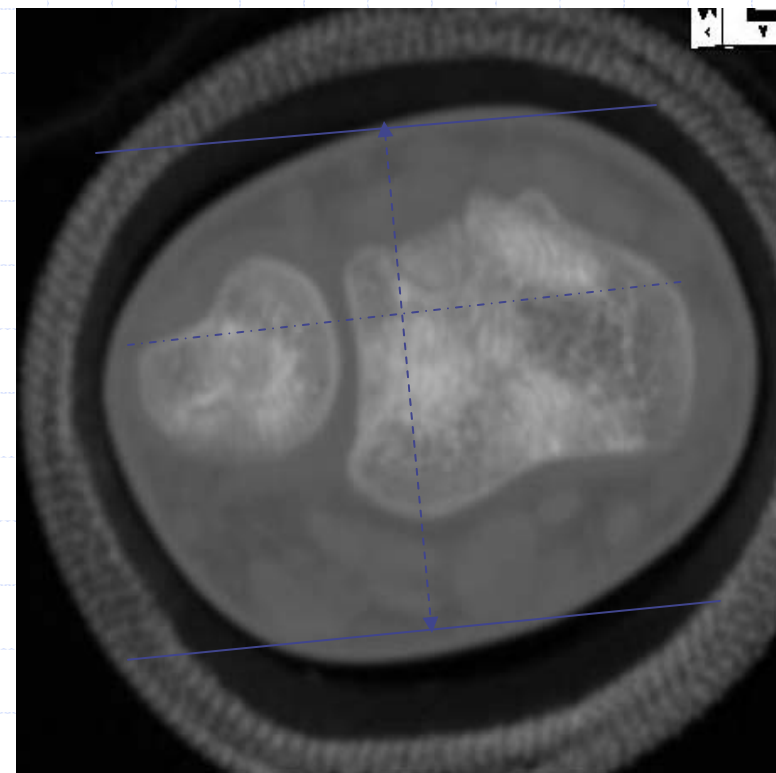
Coronal Imaging Plane

Relevant Anatomy



Coronal Imaging Plane

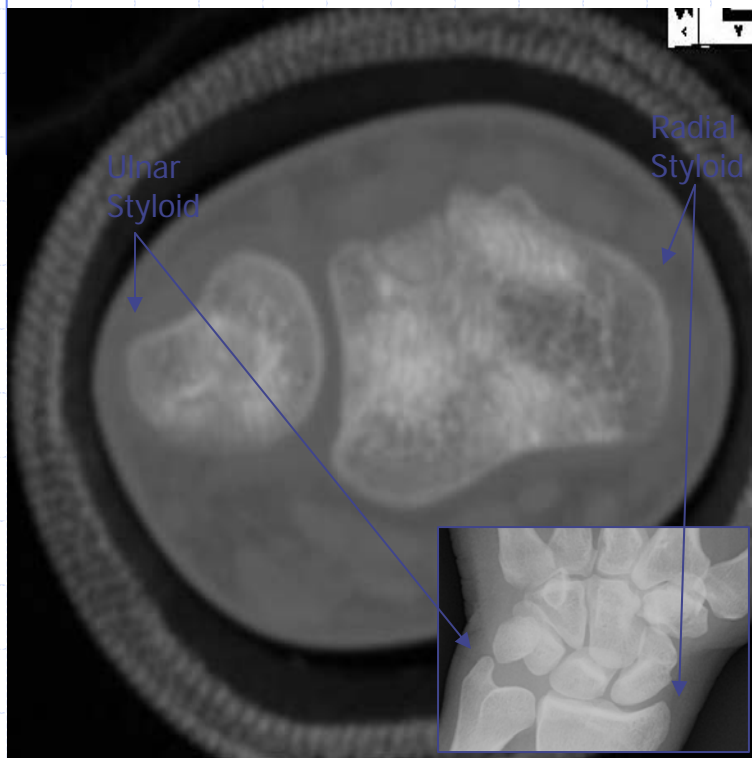
- Prescribe plane parallel to line drawn from ulnar styloid through radial styloid.
- Scan through entire wrist.



WRIST

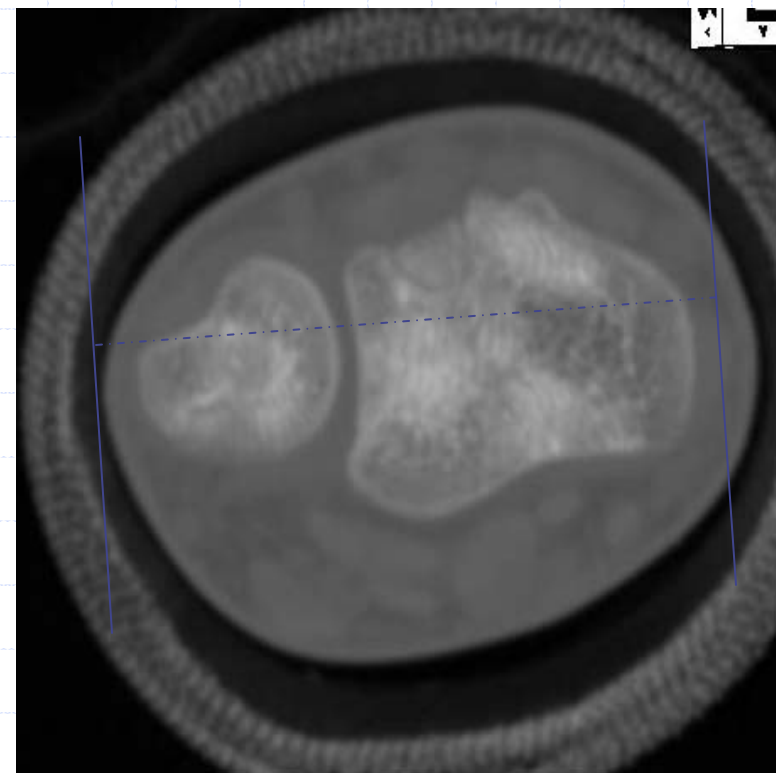
Sagittal Imaging Plane

Relevant Anatomy



Sagittal Imaging Plane

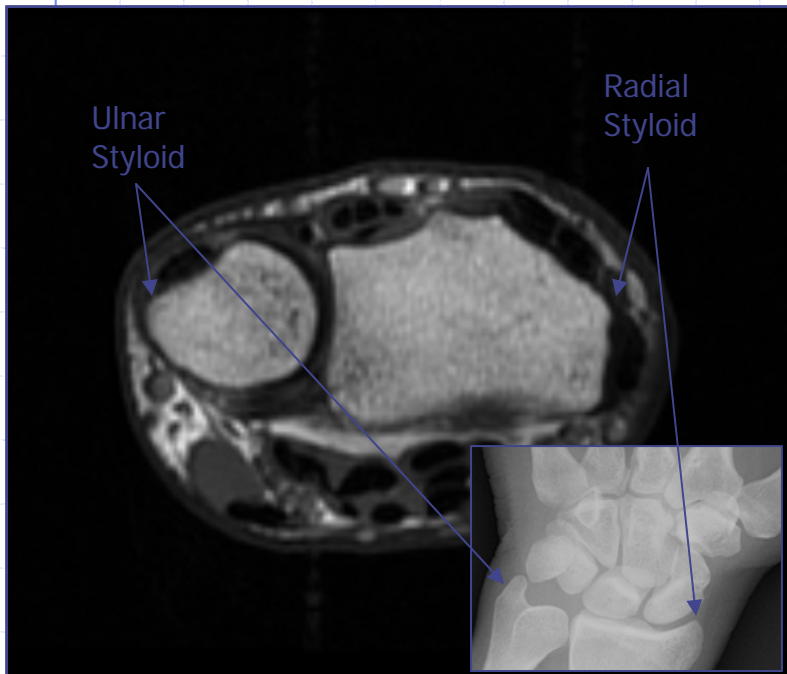
*Prescribe plane perpendicular to coronal plane (©).
Scan through entire wrist.



WRIST

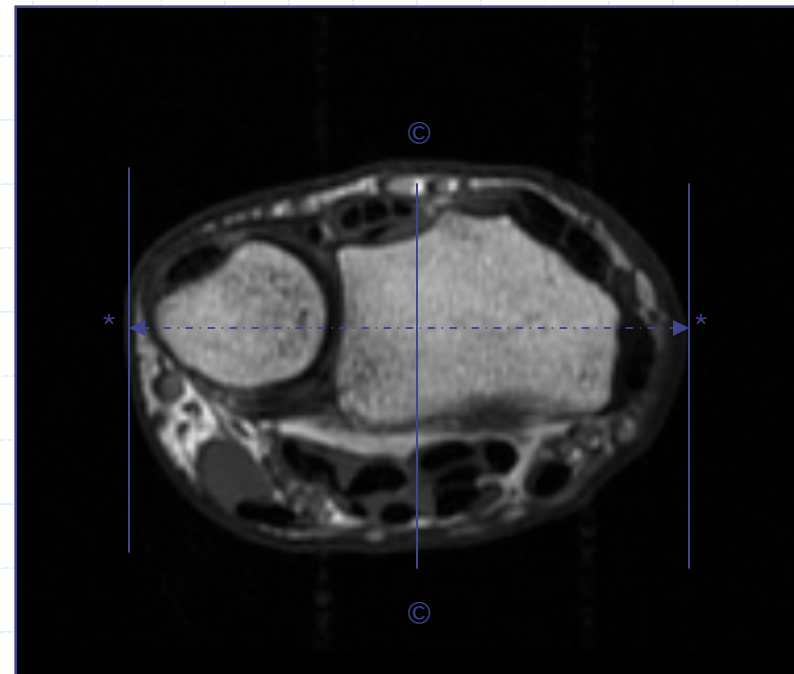
Sagittal Imaging Plane

Relevant Anatomy



Sagittal Imaging Plane

*Prescribe plane perpendicular to coronal plane (©).
Scan through entire wrist.





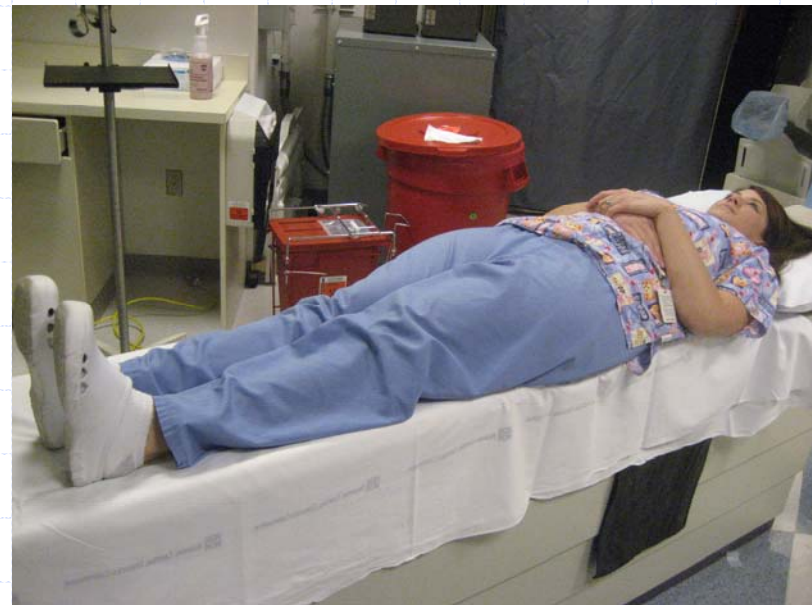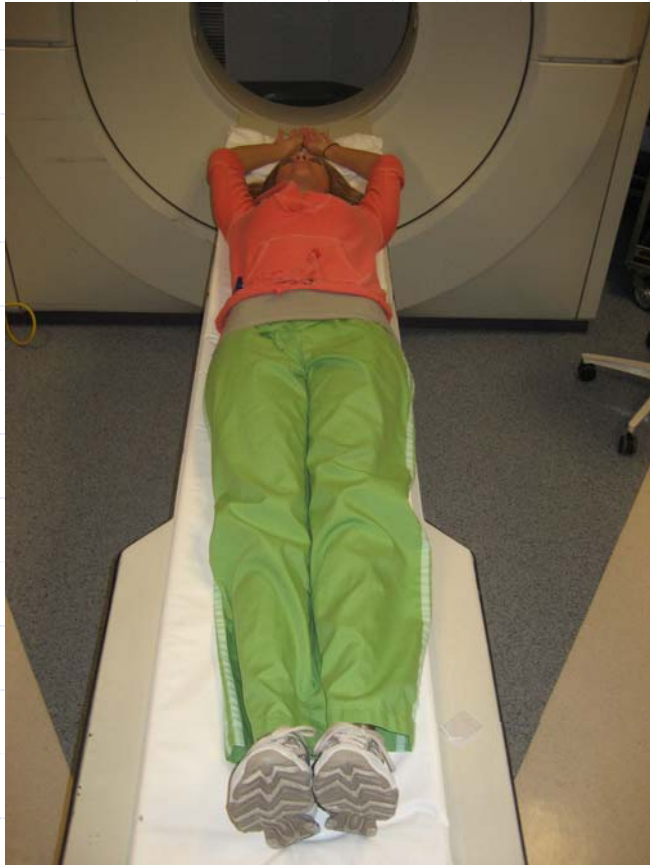
LOWER EXTREMITY

HIP

◆ Positioning

- Patient Supine
- Legs flat on table

HIPS

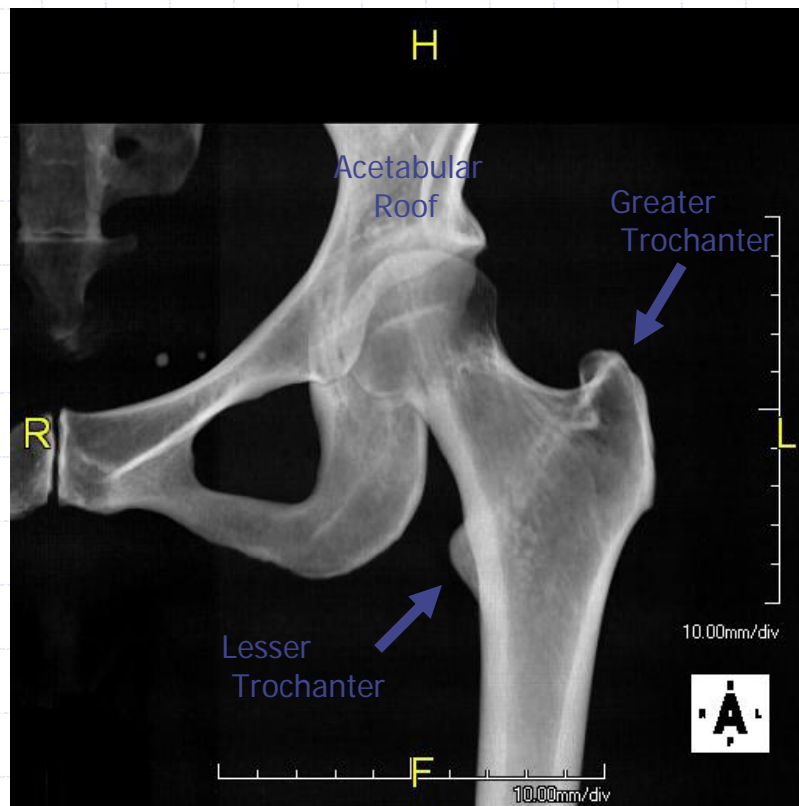


HIP

Gantry Tilt	FOV	KV	mA
0	Large	140	200
	Slice (mm)	Interval (mm)	Type/Plane
Reconstruct	1.25	0.62	-Bone -Soft Tissue
Reformat	2	2	-Axial -Coronal -Sagittal

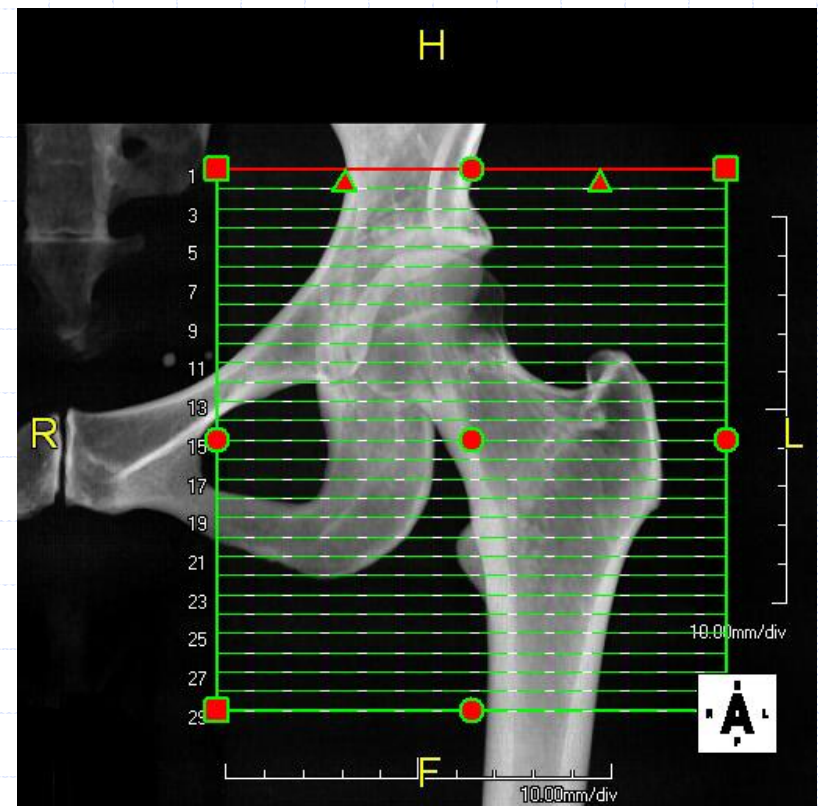
HIP

Relevant Anatomy



Scanning Plane

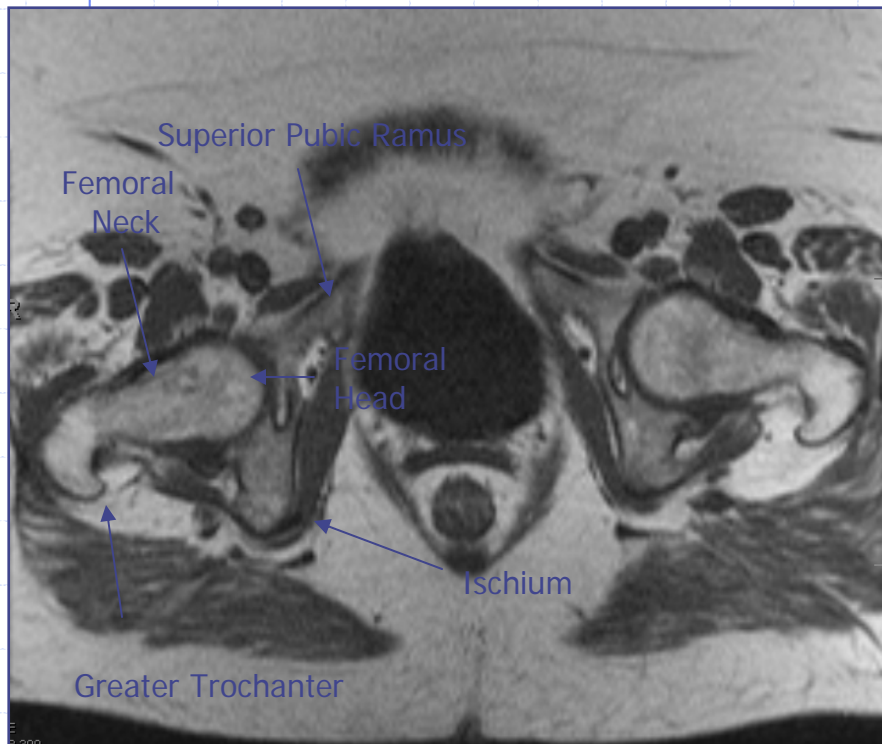
- Prescribe plane parallel to acetabular roof
- Scan from acetabular roof through lesser trochanter



HIP

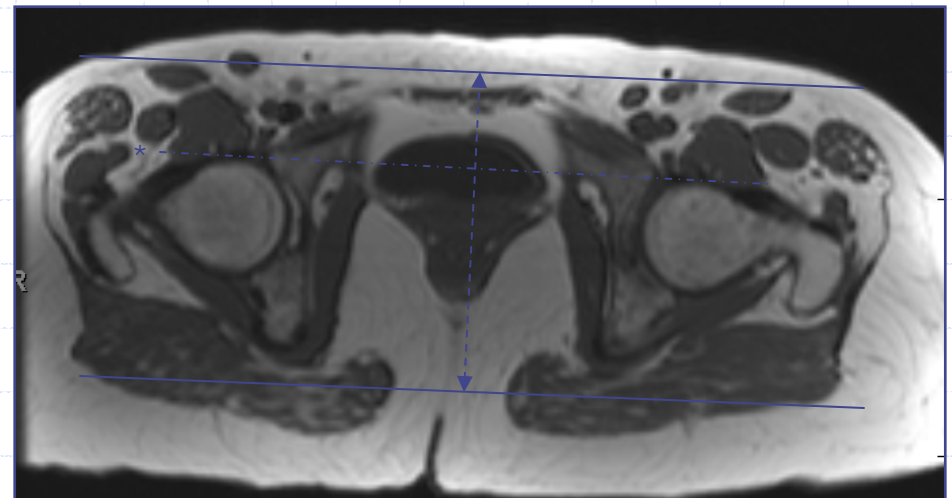
Coronal Imaging Plane

Relevant Anatomy



Coronal Imaging Plane

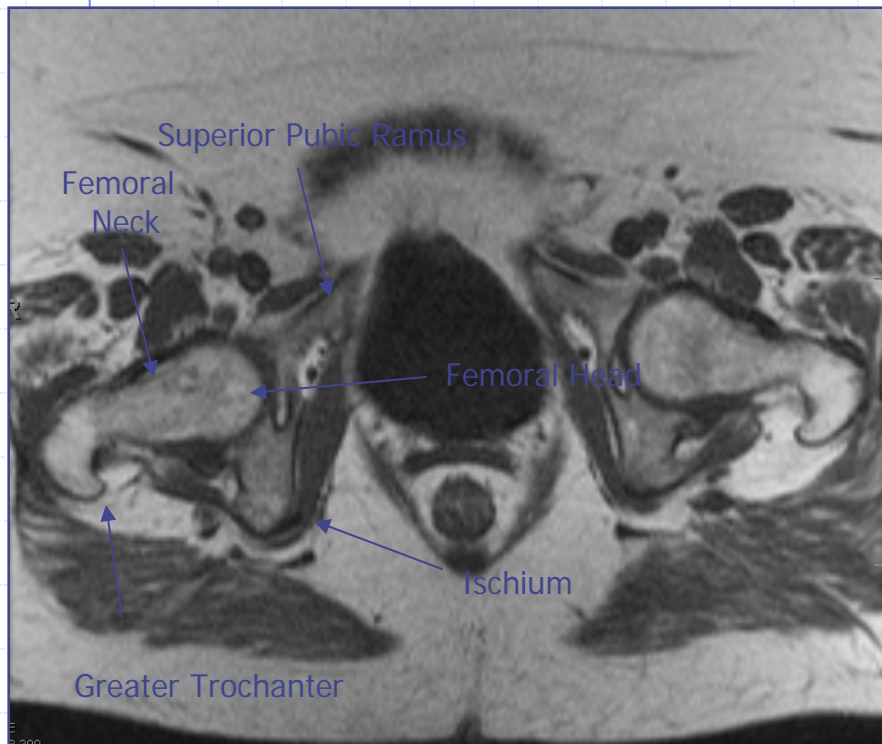
*Prescribe plane parallel femoral heads.
Scan from ischium through pubic symphysis.



HIP

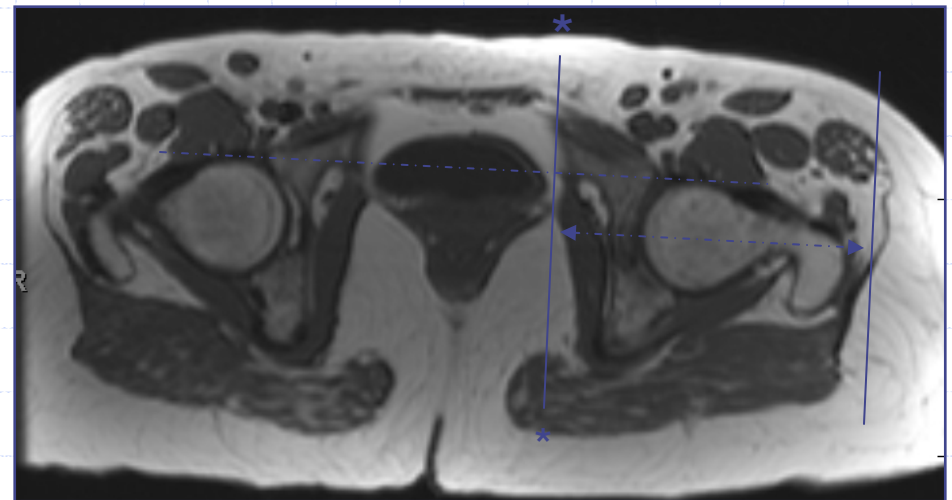
Sagittal Imaging Plane

Relevant Anatomy



Sagittal Imaging Plane

*Prescribe plane perpendicular to coronal plane.
Scan from acetabulum through greater trochanter.

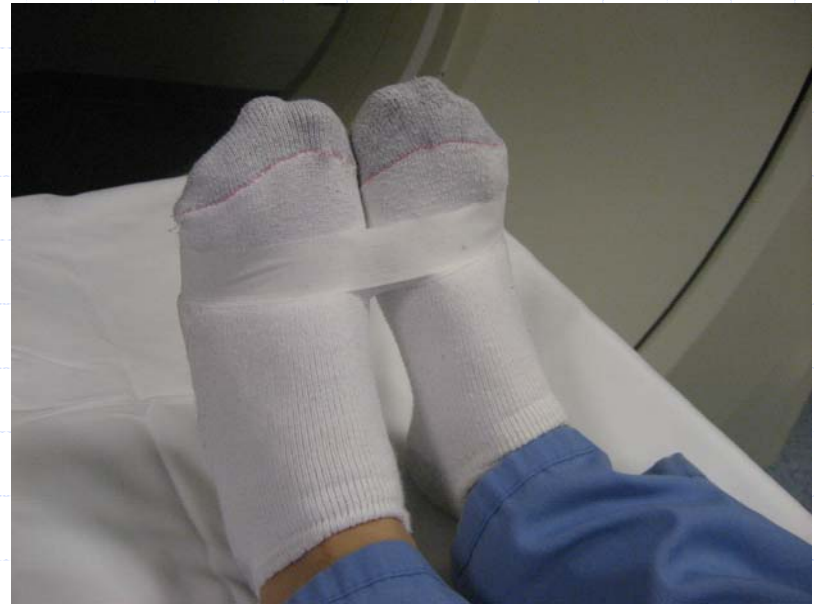
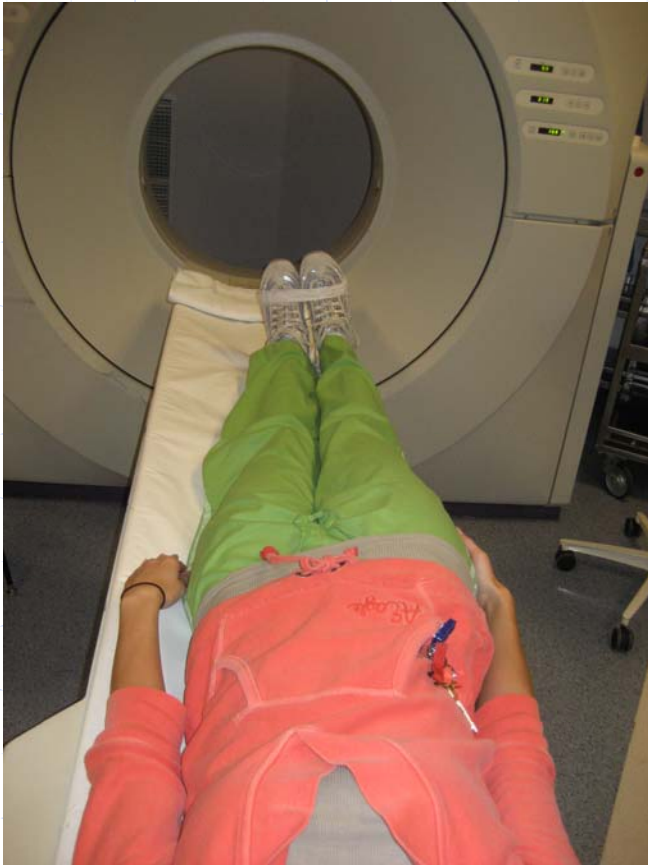
KNEE

◆ Positioning:

- Patient Supine with feet first into scanner
- Keeps knees extended, side-by-side.
- Tape the feet together with toes pointing up to help keep the knees from moving.
- Slide patient so that the knee being scanned is in the center of the table

KNEE

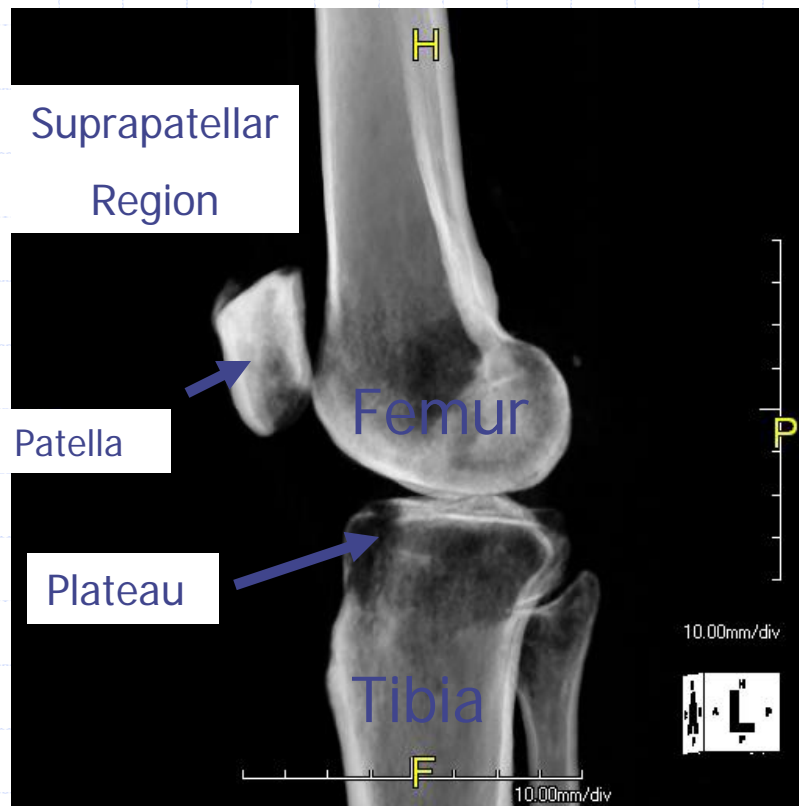


KNEE

Gantry Tilt	FOV	KV	mA
0	Small	120	150
	Slice (mm)	Interval (mm)	Type/Plane
Reconstruct	0.625	0.5	-Bone -Soft Tissue
Reformat	0.8	1.5	-Axial -Coronal -Sagittal

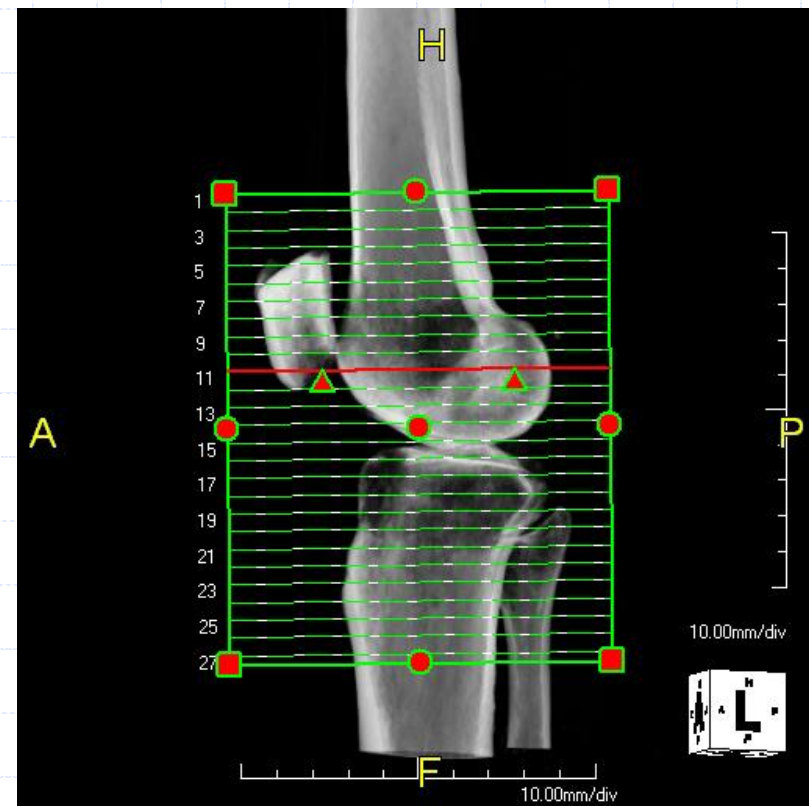
KNEE

Relevant Anatomy



Scanning Plane

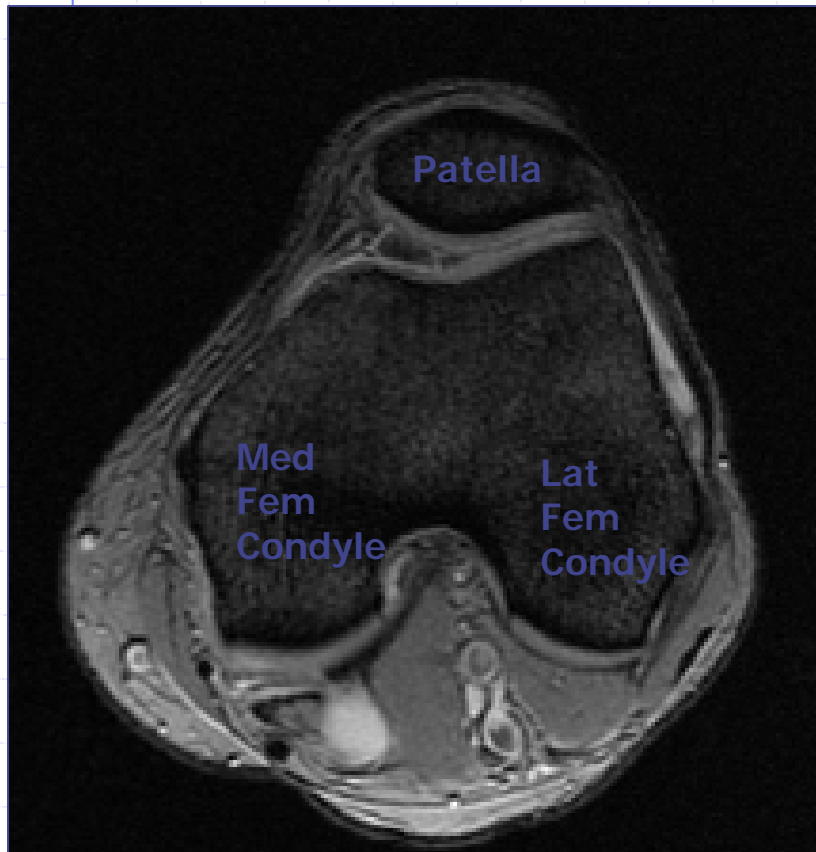
- Prescribe plane parallel to axis of the tibial plateau.
- Scan knee from suprapatellar region to the proximal tibia



KNEE

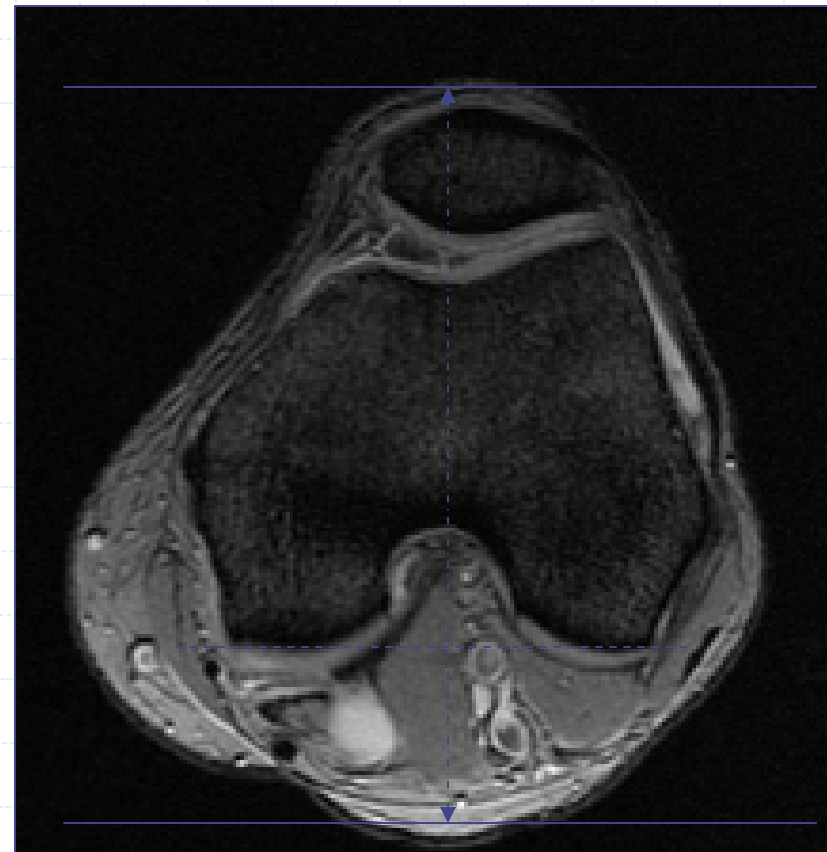
Coronal Imaging

Relevant Anatomy



Coronal Imaging Plane

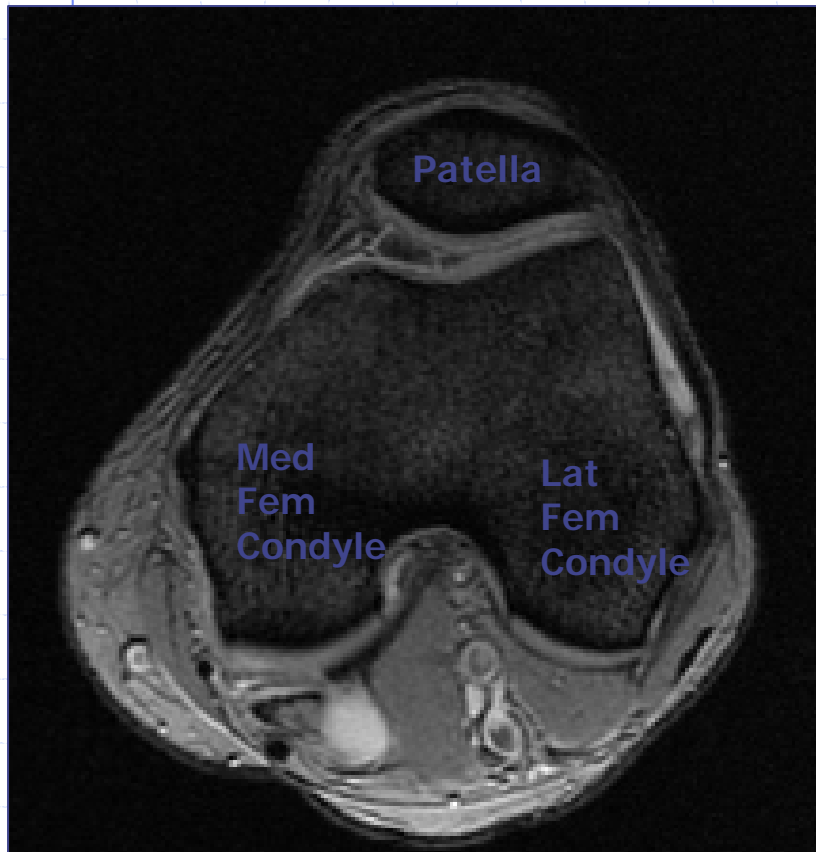
Prescribe plane with line parallel to femoral condyles. Image entire knee.



KNEE

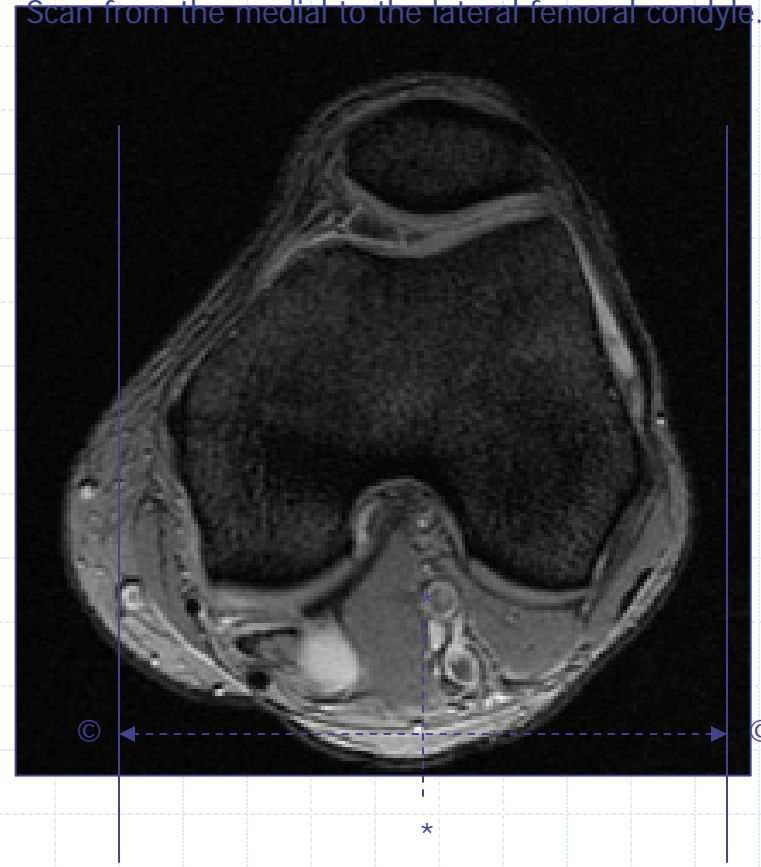
Sagittal Imaging Plane

Relevant Anatomy



Sagittal Imaging Plane

*Prescribe plane perpendicular to coronal plane (©).
Scan from the medial to the lateral femoral condyle.

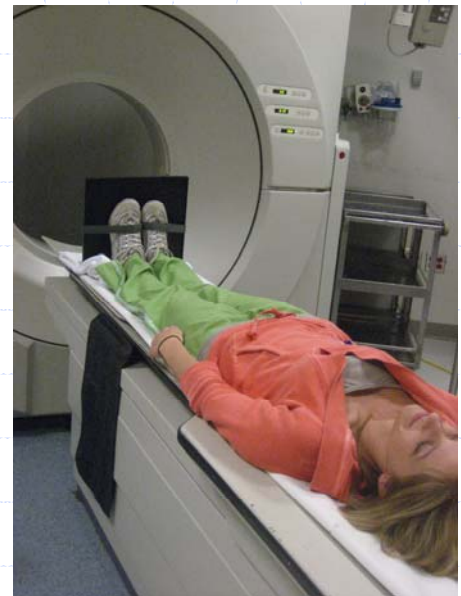
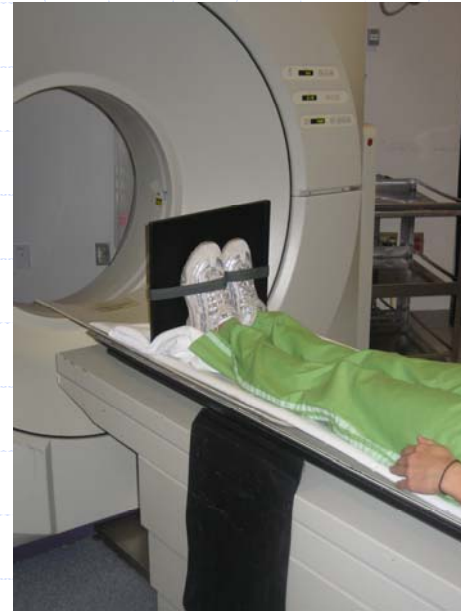
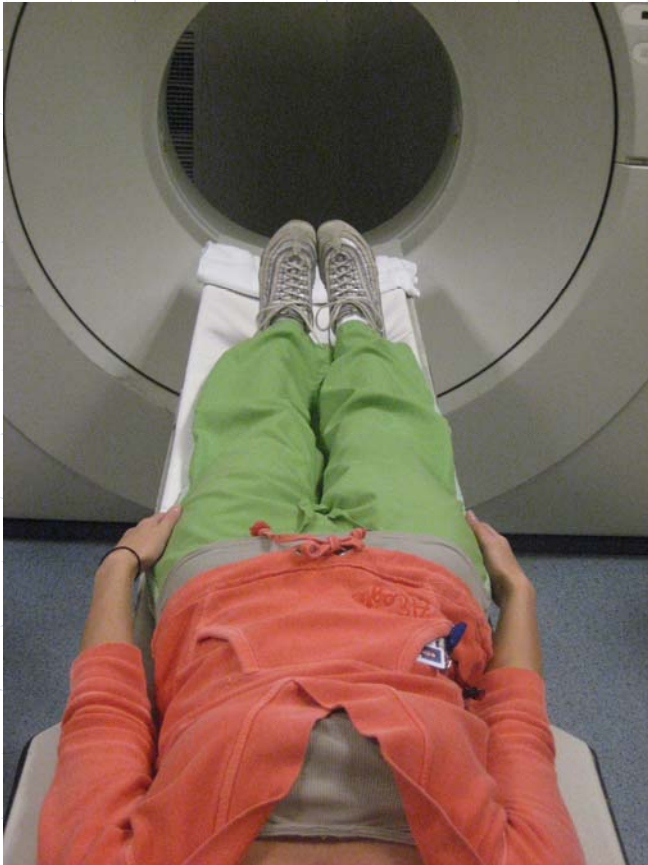ANKLE

◆ Positioning:

- Patient supine
- Center in scanner both feet or foot of interest (use foot holder, if available). If imaging both feet, bring them together
- Toes pointing straight up.
- Foot inverted slightly

ANKLE

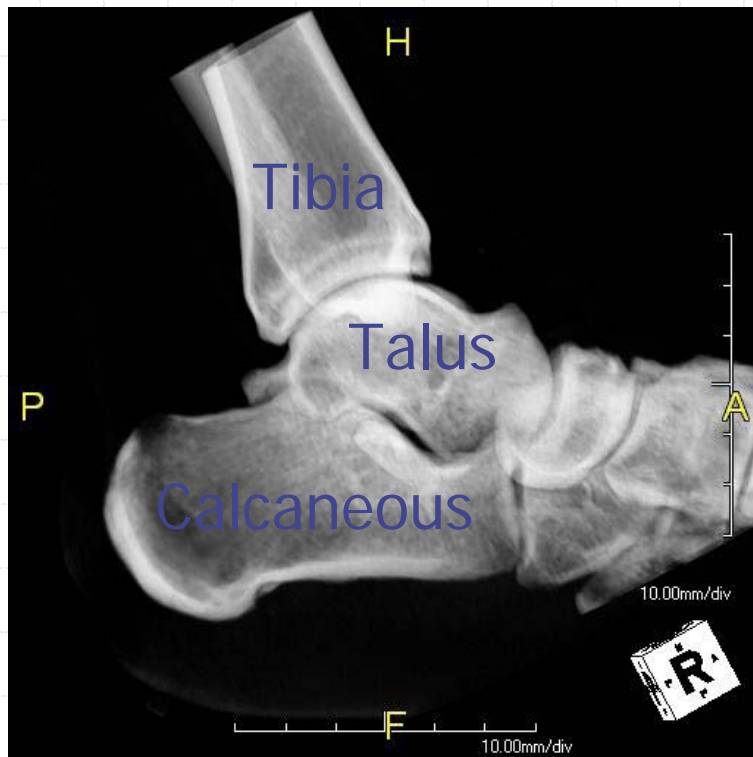


ANKLE

Gantry Tilt	FOV	KV	mA
0	Small	120	150
	Slice (mm)	Interval (mm)	Type/Plane
Reconstruct	0.625	0.3	-Bone -Soft Tissue
Reformat	0.8	1.5	-Axial -Coronal -Sagittal

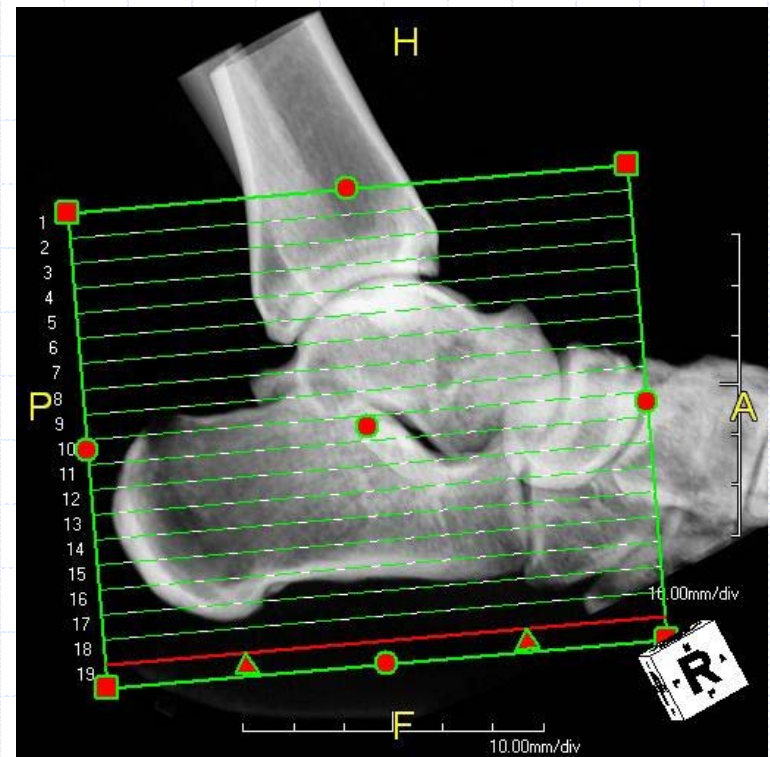
ANKLE

Relevant Anatomy



Scanning Plane

- Prescribe plane parallel to axis of calcaneus.
- Scan ankle from distal tibia through beyond the inferior calcaneus

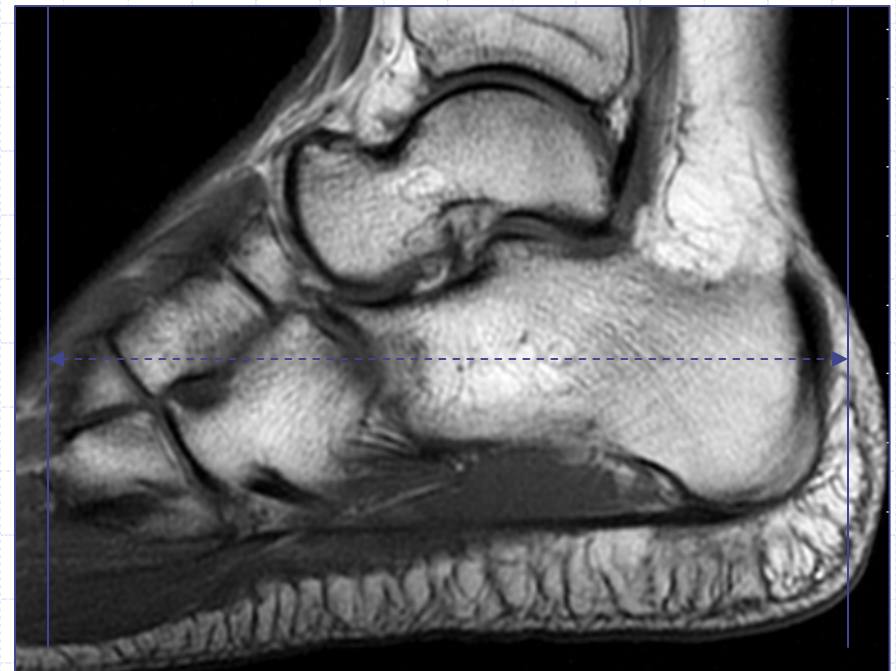
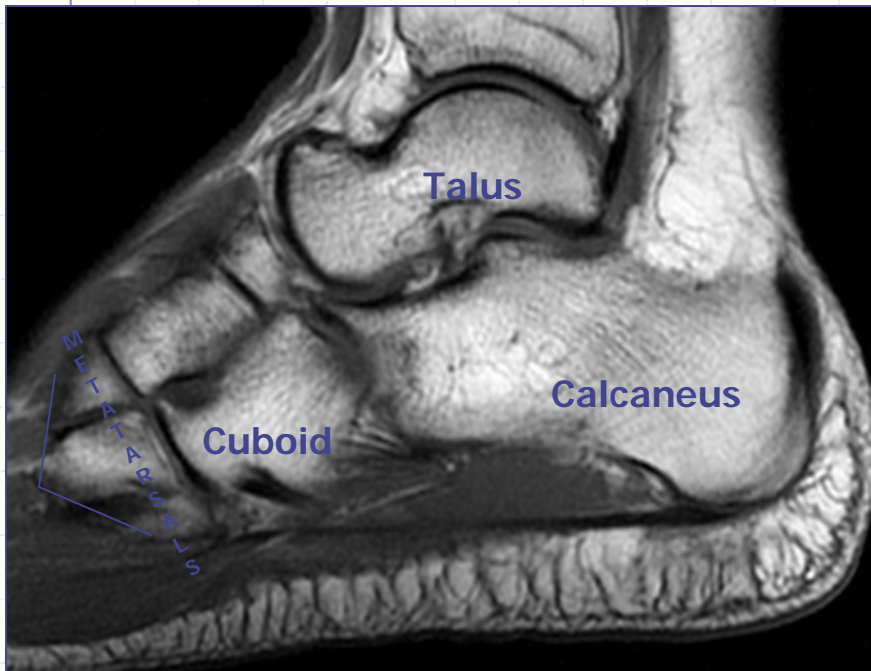


ANKLE

Coronal Imaging Plane

Relevant Anatomy

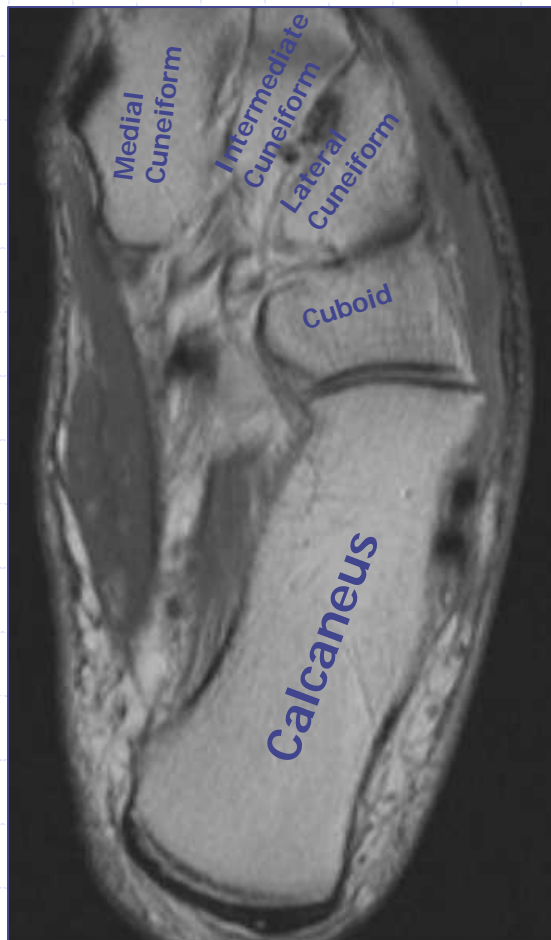Coronal Imaging Plane
Prescribe plane perpendicular to axial imaging plane. Scan ankle from calcaneus through metatarsal bases.



ANKLE

Sagittal Imaging Plane

Relevant Anatomy



Sagittal Imaging Plane

Prescribe plane with line bisecting calcaneus. Scan through entire foot.

